

Editorial

From nuchal translucency to intracranial translucency: towards the early detection of spina bifida

R. CHAOUI†* and K. H. NICOLAIDES‡

†Prenatal Diagnosis and Human Genetics, Berlin, Germany and
‡Harris Birthright Research Centre for Fetal Medicine, King's
College Hospital and Department of Fetal Medicine, University
College, London, UK *Correspondence (e-mail:
chaoui@feindiagnostik.de)

It is now clear that the vast majority of major fetal abnormalities can be diagnosed prenatally by ultrasound, that most of these abnormalities can be detected in the first trimester of pregnancy and that women want first-trimester rather than later diagnosis.

It is also clear that effective diagnosis of fetal abnormalities often necessitates the identification of easily recognizable markers which direct the attention of the sonographer to the specific abnormality. Good examples of such markers are the scalloping of the frontal bones (the 'lemon' sign) and caudal displacement of the cerebellum (the 'banana' sign), observed in the second trimester in most fetuses with open spina bifida, and increased nuchal translucency thickness (NT) which identifies in the first trimester the majority of fetuses with major aneuploidies, lethal skeletal dysplasias and a high proportion of major cardiac defects.

It is now widely accepted that increased NT at 11–13 weeks is the single most effective marker of trisomy 21 and all other major aneuploidies. First-trimester screening by a combination of maternal age, fetal NT, nasal bone, Doppler assessment of blood flow in the ductus venosus and across the tricuspid valve together with maternal serum free β -hCG and PAPP-A can identify more than 95% of all major aneuploidies for a screen-positive rate of less than 3%.

A major remaining challenge in first-trimester ultrasonography has been the diagnosis of open spina bifida. This challenge, however, may now have been resolved by the realization that open spina bifida can be suspected by an easily detectable marker within the brain in the same mid-sagittal plane of the fetal face as for measurement of NT and assessment of the nasal bone. In normal fetuses the fourth cerebral ventricle presents as an intracranial translucency (IT) parallel to the NT, while in fetuses with open spina bifida there may be absence of the IT¹.

In almost all cases of open spina bifida there is an associated Arnold–Chiari malformation, which is



thought to be the consequence of leakage of cerebrospinal fluid into the amniotic cavity and hypotension in the subarachnoid spaces leading to caudal displacement of the brain and obstructive hydrocephalus. In the second trimester of pregnancy the manifestations of Arnold–Chiari malformation are the lemon and banana signs and in the first trimester caudal displacement of the brain results in compression of the fourth ventricle and loss of the normal IT^{1–4}.

Measurement of IT is similar to that of NT

The two lines that define the IT are the posterior border of the brain stem anteriorly and the choroid plexus of the fourth ventricle posteriorly (Figure 1). Its measurement is similar to that of NT. The exact mid-sagittal plane of the fetal face should be obtained and the image should be magnified so that only the fetal head and upper thorax are included. The exact mid-sagittal plane of the fetal face is defined by the echogenic tip of the nose and rectangular shape of the palate anteriorly, the translucent thalamus in the center and the nuchal membrane posteriorly. Rotation of the head by about 10° away from the midline results in non-visibility of the tip of the nose and the appearance of the maxillary bone as an echogenic structure between the nasal bone above and the anterior part of the palate below. With further rotation, by about 15° from the midline, the nasal bone disappears and there is enlargement of the maxillary bone and coalescence with the palate.

At 11–13 weeks the brain stem appears hypoechoic (dark gray) whereas the IT is anechoic (black) (Figure 1). Posterior to the IT is the future cisterna magna. In the mid-sagittal plane the IT has a slightly curved appearance and the widest anteroposterior diameter is in the middle part of the fourth ventricle. In measuring IT, as for NT, we recommend selecting the translucency with the widest

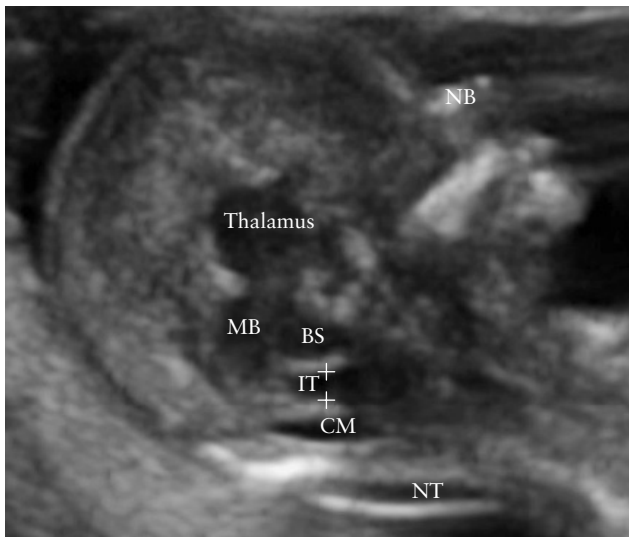
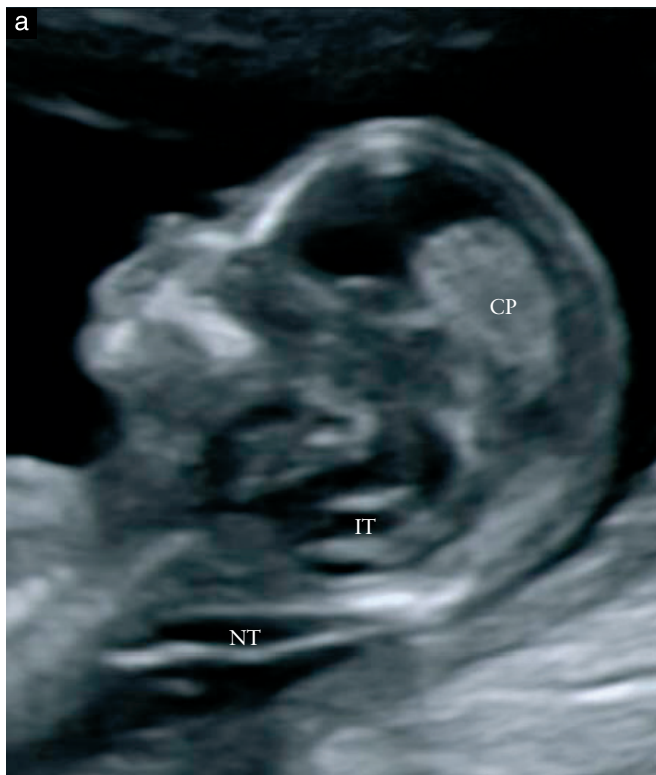
Figure 1 Exact mid-sagittal plane of the fetal face at 13 weeks (crown–rump length, 69 mm) showing the nasal bone (NB), nuchal translucency (NT), thalamus, midbrain (MB), brain stem (BS), cisterna magna (CM) and fourth ventricle. The fourth ventricle appears as an intracranial translucent (IT) area between two echogenic borders, the posterior border of the brain stem anteriorly and the choroid plexus of the fourth ventricle posteriorly. Measurement of the IT is achieved by placing the calipers on the anterior and posterior echogenic borders of the fourth ventricle.

diameter and placing the calipers on the anterior and posterior echogenic borders.



Exact mid-sagittal and parasagittal planes

The exact mid-sagittal plane is ideal for measuring IT as it is for measuring NT and assessing the nasal bone. In this plane we can identify the fluid within the third ventricle between the right and left thalami and the aqueduct of Sylvius between the cerebral peduncles, although the thalami and peduncles themselves are not visible.

The intracranial structures, including the thalamus, midbrain, brain stem, fourth ventricle and cisterna magna, can be identified easily in a slightly deviated parasagittal plane. Indeed, as shown in transverse view in Figure 2, the fourth ventricle remains wide on either side of the midline, therefore the effect of measuring the IT in planes that are slightly deviated from the exact mid-sagittal one should be minimal.

Gestational age for assessment of IT

The optimal gestational age for measurement of fetal NT is 11 + 0 to 13 + 6 weeks. The reasons for selecting 11 weeks as the earliest gestation are: firstly, screening necessitates the availability of a diagnostic test and chorionic villus sampling before this gestation is associated with transverse limb reduction defects and secondly, many major fetal abnormalities can be diagnosed at the NT scan, provided the minimum gestation is 11 weeks. The reasons for selecting 13 weeks and 6 days as the upper limit are: firstly, to provide women with affected fetuses

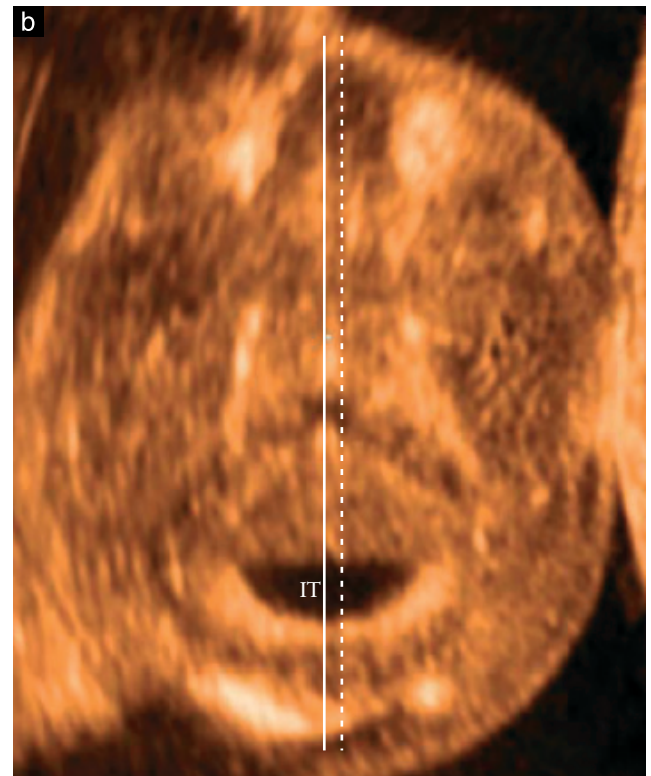


Figure 2 (a) Parasagittal plane of the fetal face at 13 weeks, with visible choroid plexus (CP). (b) The transverse view of the head at the level of the fourth ventricle obtained transvaginally demonstrates that mild deviations in insonation from the midline (solid line) have minimal effect on the measurement of intracranial translucency (IT). NT, nuchal translucency.

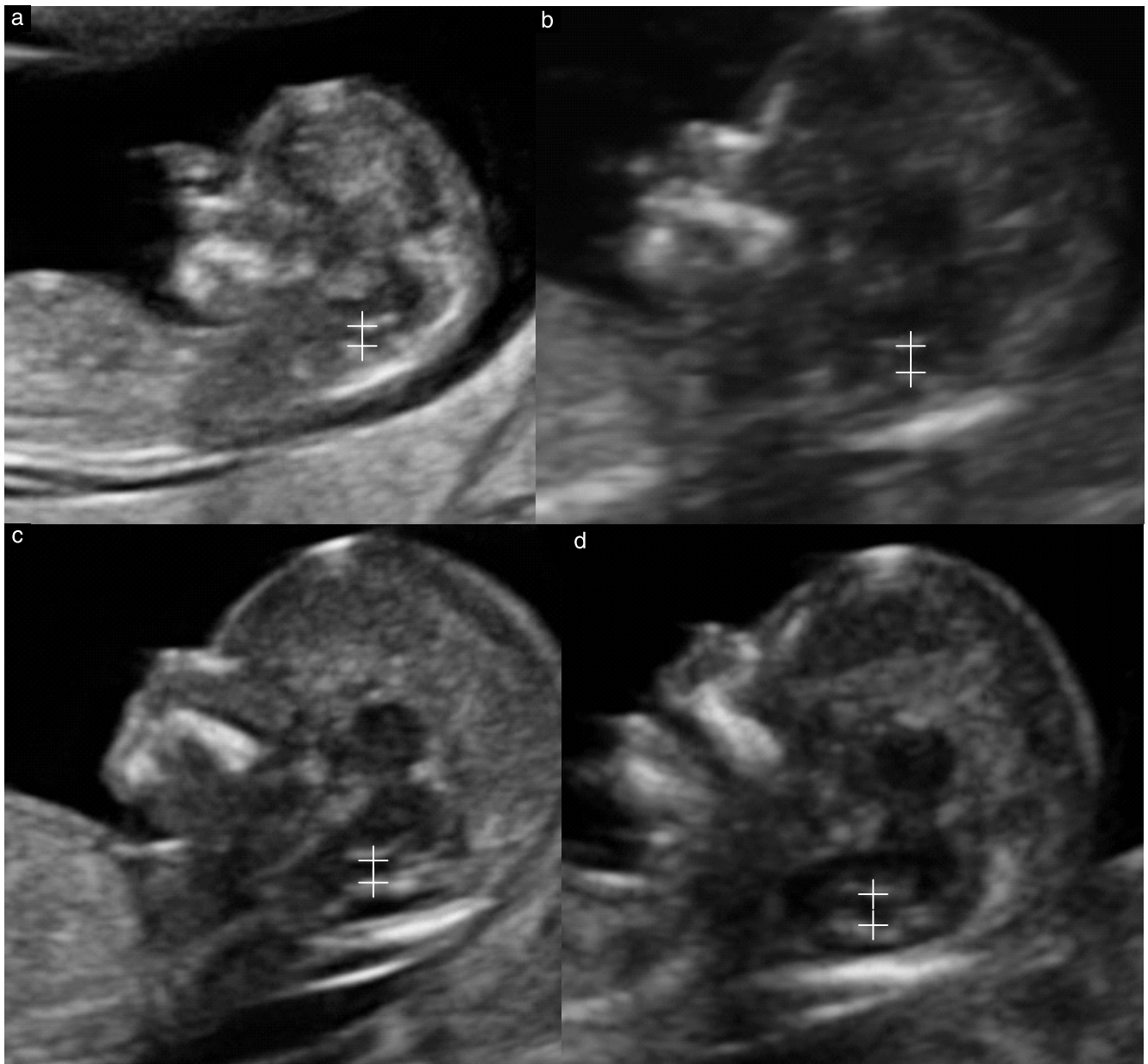


Figure 3 Intracranial translucency (calipers) in four fetuses scanned transabdominally at 11–13 weeks. The fetal crown–rump length was 48 mm in the fetus in (a), 63 mm in (b), 75 mm in (c) and 81 mm in (d).

the option of first- rather than second-trimester termination, secondly, the incidence of abnormal accumulation of nuchal fluid in chromosomally abnormal fetuses decreases after 13 weeks and thirdly, the success rate for taking a measurement decreases after 13 weeks because the fetus becomes vertical, making it more difficult to obtain the appropriate image.

At 11–13 weeks it is possible to diagnose severe brain abnormalities, including holoprosencephaly, ventriculomegaly, acrania-exencephaly and encephalocele. Within the gestational age range of 11–13 weeks the anteroposterior diameter of the IT increases with fetal crown–rump length (CRL) from a median of 1.5 mm at a CRL of 45 mm to 2.5 mm at a CRL of 85 mm (Figure 3)¹. Extensive sonographic studies of the developing human brain have reported that the fourth ventricle is easily

identified from 8 weeks as a hypoechoic structure^{5–9}. The extent to which the IT in fetuses with spina bifida is altered before 11 weeks remains to be determined. The fourth ventricle can also be identified easily after 13 weeks and the diameter increases with gestational age¹⁰. However, from the 14th week onwards open spina bifida can be unmasked easily by the lemon and banana signs and it is therefore unlikely that measurement of IT will be used for this purpose in the second trimester of pregnancy.

Fetal position for assessment of IT

At 11–13 weeks the fetal nasal bone is considered to be absent in about 60% of fetuses with trisomy 21 compared with 1–3% of euploid fetuses and therefore assessment

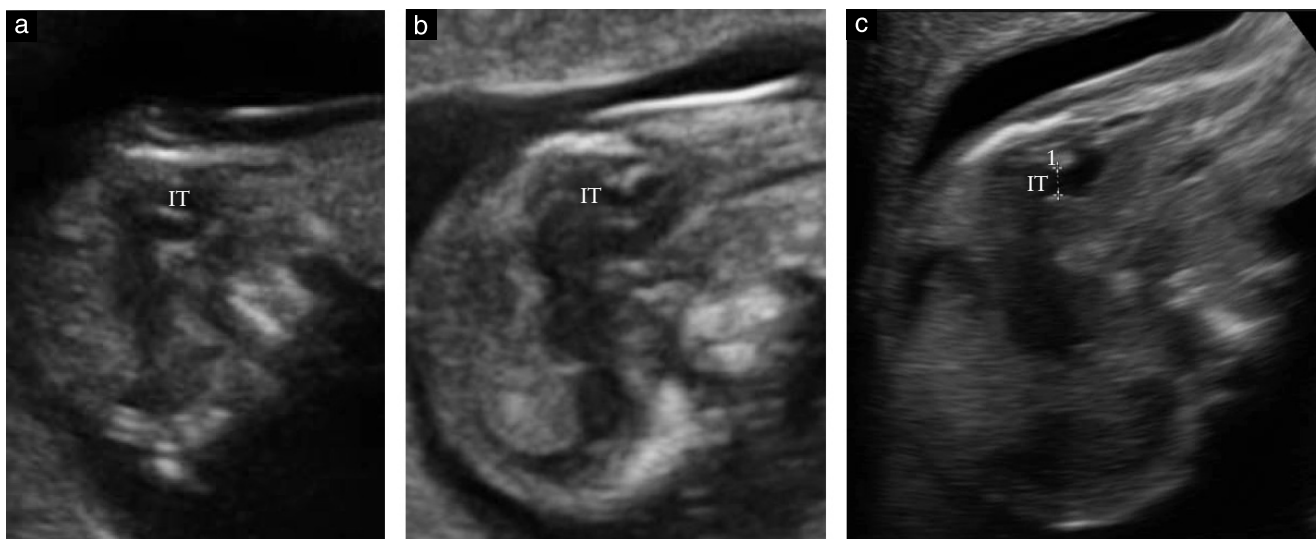


Figure 4 Visualization of the intracranial translucency (IT) in three fetuses in a prone position at 12 weeks' gestation (crown–rump lengths, 62–64 mm). There is shadowing of the brain by the occipital bone. Images (a) and (b) were obtained by transabdominal sonography and image (c) was obtained transvaginally.

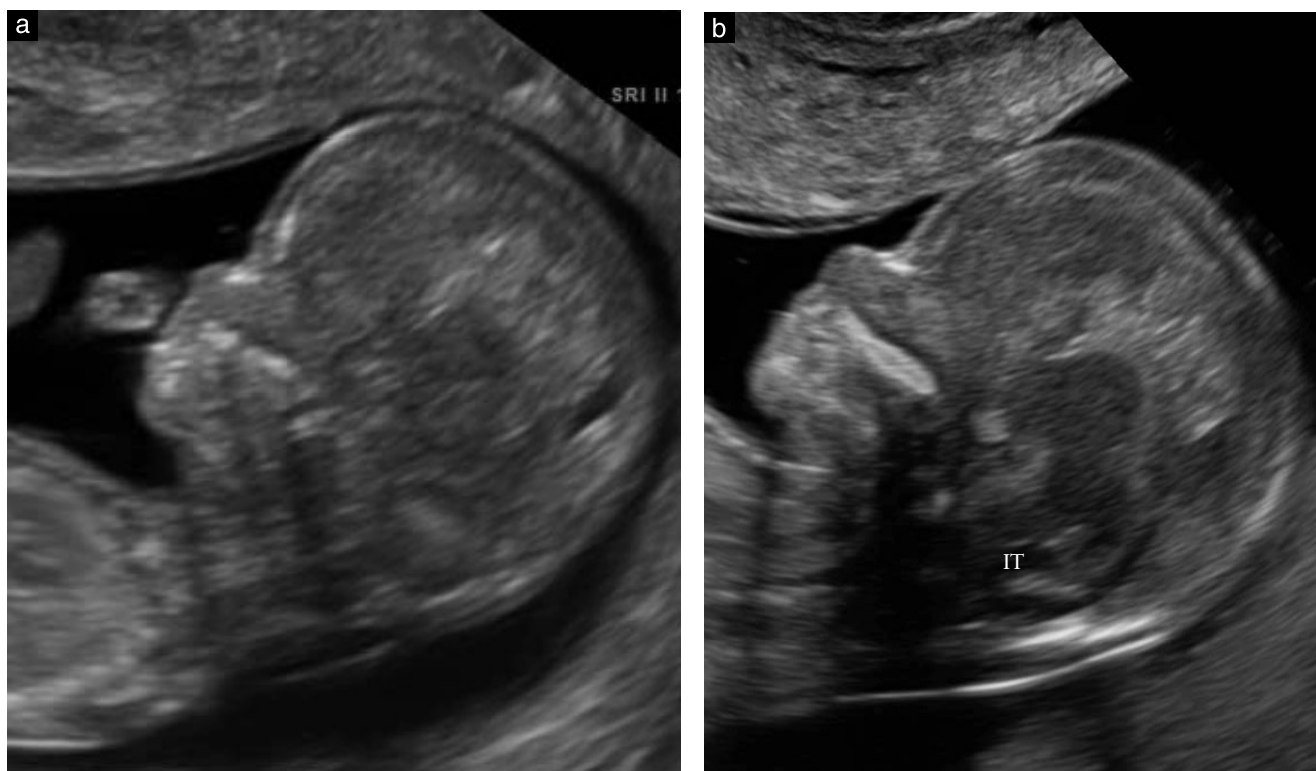


Figure 5 Transvaginal sonography (mid-sagittal plane) in two fetuses at 12 weeks. Although in both cases the resolution was high, in (a) the fourth ventricle and other structures of the brain are not visualized clearly and, although in (b) the intracranial translucency (IT) is clearly visible, the contrast discrimination is poorer than that of mid-sagittal planes of the face obtained transabdominally (cf. Figures 1–3).

of the nasal bone improves the performance of first-trimester screening for aneuploidies. Although the nasal bone can be examined when the fetus is in the prone position the assessment is easier when the fetus is facing the transducer.

As for the nasal bone, assessment of IT is preferable when the fetus is facing the transducer. Although the fourth ventricle may be visible when the fetus is in the prone position, adequate examination of the fetal brain

is often hampered by shadowing from the fetal occipital bone (Figure 4).

Transabdominal vs. transvaginal assessment of IT

The exact mid-sagittal plane of the fetal face necessary for measurement of fetal NT and assessment of the nasal bone is obtained more easily by transabdominal than transvaginal sonography, because the latter allows

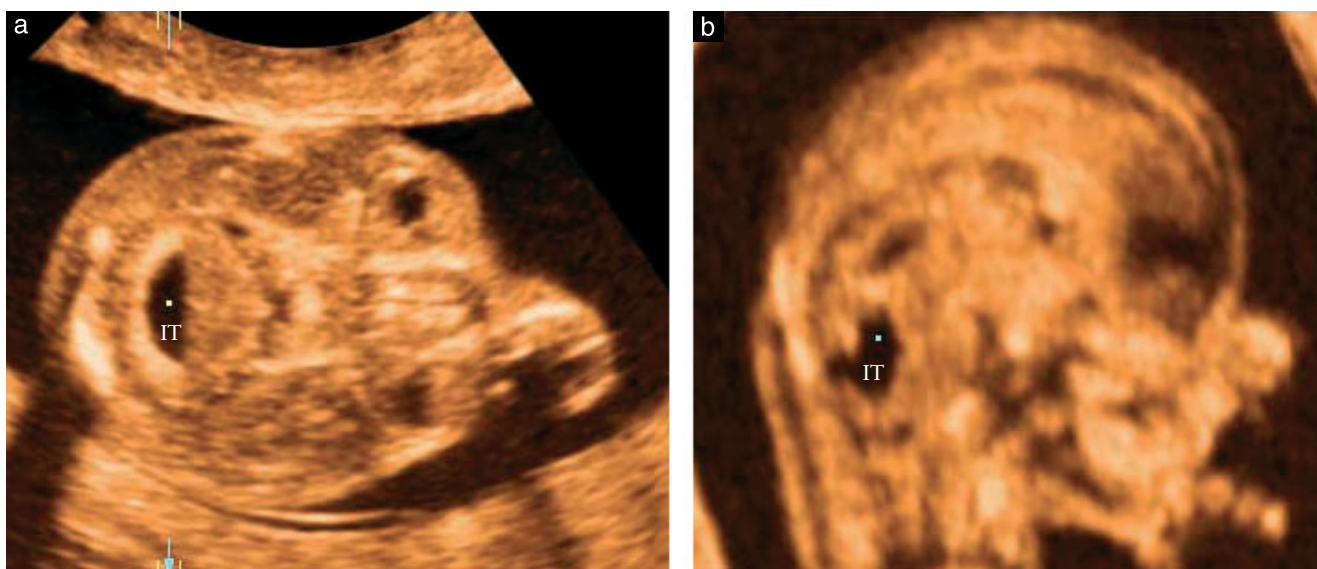


Figure 6 Three-dimensional volume of the fetal head at 12 weeks acquired transvaginally and displayed in the orthogonal mode combined with static volume contrast imaging. The reference dot is placed in the center of the fourth ventricle (a) and the image is then adjusted to obtain a reconstructed mid-sagittal plane of the brain (b) for measurement of the intracranial translucency (IT).

less transducer manipulation. However, the objective of the 11–13-week scan is not restricted to screening for fetal aneuploidies but includes the early diagnosis of all major defects through a systematic examination of the whole fetal anatomy. Since the resolution of transvaginal sonography in the assessment of most fetal organs is superior to that of the transabdominal route, fetal medicine experts often use both approaches for detailed early fetal examination.

The fourth cerebral ventricle can be visualized both transabdominally and transvaginally. However, as in the case of fetal NT and nasal bone, assessment and measurement of IT is best carried out in the mid-sagittal plane of the fetal face, which is easier to obtain transabdominally. Additionally, with transvaginal sonography even in the mid-sagittal plane of the fetal face the difference in contrast between the IT and surrounding brain is often poor (Figure 5). If the transvaginal route is chosen for assessment of the fourth ventricle it is preferable that the transducer is directed towards the posterior fossa (Figure 4c) rather than the face (Figure 5a).

Three-dimensional ultrasound for assessment of IT

Three-dimensional ultrasound is useful in assessing IT particularly when it is difficult to obtain the mid-sagittal plane directly by two-dimensional ultrasound. In such cases a transverse view of the fetal head at the level of the fourth ventricle is obtained. This is best achieved by transvaginal sonography because the resolution is higher. A three-dimensional volume is then acquired and displayed in the orthogonal mode. The reference dot is placed in the center of the fourth ventricle and the image is then rotated to align the midline and obtain a mid-sagittal plane of the brain for IT measurement (Figure 6). This is similar to the approach used in the second-trimester scan for

demonstration of other fetal intracerebral structures, such as the corpus callosum and vermis¹¹. To enhance image quality, a thin three-dimensional slice (volume contrast) instead of a simple plane can be used, for example by applying a static volume contrast imaging tool.

Closing the loop in the 11–13-week scan

In the 1980s, the main method of screening for open spina bifida was by maternal serum α -fetoprotein at around 16 weeks and the method of diagnosis was amniocentesis and measurement of amniotic fluid α -fetoprotein and acetyl cholinesterase. Although it was possible to diagnose the condition by ultrasonographic examination of the spine, the sensitivity of this test was low^{12,13}. However, the observation that open spina bifida was associated with the lemon and banana signs has led to the replacement of biochemical assessment with second-trimester ultrasonography, both for screening and for diagnosis of this abnormality².

In the 1970s, the main method of screening for trisomy 21 was by maternal age and in the 1980s it was by maternal serum biochemistry and detailed ultrasonographic examination in the second trimester. In the 1990s the emphasis shifted to the first trimester when it was realized that the great majority of trisomic fetuses have increased NT that can be detected easily in a mid-sagittal plane of the fetal face at 11–13 weeks. Improved performance of screening was achieved subsequently with the observation that in the same mid-sagittal plane as for measurement of NT it was possible to examine the nasal bone, which is often absent in trisomic fetuses.

It is now clear that in this same mid-sagittal plane the fourth cerebral ventricle is easily visible as an IT and that at least in some cases of open spina bifida, caudal displacement of the brain is evident from the first trimester,

resulting in loss of the normal IT. It is certain that sonographers involved in first-trimester screening for aneuploidies will endeavour to obtain the exact mid-sagittal plane of the fetal face and as their eyes move from the NT to the nasal bone it is inevitable that they will also glance at the IT. If this is not visible the sonographers will be alerted to the possibility of an underlying open spina bifida and will undertake detailed examination of the fetal spine.

Prospective large studies will determine the proportion of affected fetuses presenting with absent IT and the extent to which the 11–13-week scan can provide an effective method for early diagnosis of open spina bifida.

REFERENCES

1. Chaoui R, Benoit B, Mitkowska-Wozniak H, Heling KS, Nicolaidis KH. Assessment of intracranial translucency (IT) in the detection of spina bifida at the 11–13-week scan. *Ultrasound Obstet Gynecol* 2009; **34**: 249–252.
2. Nicolaidis KH, Campbell S, Gabbe SG, Guidetti R. Ultrasound screening for spina bifida: cranial and cerebellar signs. *Lancet* 1986; **2**: 72–74.
3. Van den Hof MC, Nicolaidis KH, Campbell J, Campbell S. Evaluation of the lemon and banana signs in one hundred and thirty fetuses with open spina bifida. *Am J Obstet Gynecol* 1990; **162**: 322–327.
4. Ghi T, Pilu G, Falco P, Segata M, Carletti A, Cocchi G, Sanini D, Bonasoni P, Tani G, Rizzo N. Prenatal diagnosis of open and closed spina bifida. *Ultrasound Obstet Gynecol* 2006; **28**: 899–903.
5. Pilu G, Ghi T, Carletti A, Segata M, Perolo A, Rizzo N. Three-dimensional ultrasound examination of the fetal central nervous system. *Ultrasound Obstet Gynecol* 2007; **30**: 233–245.
6. Blaas HG, Eik-Nes SH, Kiserud T, Hellevik LR. Early development of the hindbrain: a longitudinal ultrasound study from 7 to 12 weeks of gestation. *Ultrasound Obstet Gynecol* 1995; **5**: 151–160.
7. Timor-Tritsch IE, Monteagudo A, Santos R. Three-dimensional inversion rendering in the first- and early second-trimester fetal brain: its use in holoprosencephaly. *Ultrasound Obstet Gynecol* 2008; **32**: 744–745.
8. Kim MS, Jeanty P, Turner C, Benoit B. Three-dimensional sonographic evaluations of embryonic brain development. *J Ultrasound Med* 2008; **27**: 119–124.
9. Blaas HG, Eik-Nes SH. Sonoembryology and early prenatal diagnosis of neural anomalies. *Prenat Diagn* 2009; **29**: 312–325.
10. Goldstein I, Makhoul R, Tamir A, Rajamim BS, Nisman D. Ultrasonographic nomograms of the fetal fourth ventricle: additional tool for detecting abnormalities of the posterior fossa. *J Ultrasound Med* 2002; **21**: 849–856.
11. Pilu G, Ghi T, Carletti A, Segata M, Perolo A, Rizzo N. Three-dimensional ultrasound examination of the fetal central nervous system. *Ultrasound Obstet Gynecol* 2007; **30**: 233–245.
12. Campbell S, Pryse-Davies J, Coltart TM, Seller MJ, Singer JD. Ultrasound in the diagnosis of spina bifida. *Lancet* 1975; **1**: 1065–1068.
13. Roberts CJ, Evans KT, Hibbard BM, Laurence KM, Roberts EE, Robertson IB. Diagnostic effectiveness of ultrasound in detection of neural tube defect: the South Wales experience of 2509 scans (1977–1982) in high-risk mothers. *Lancet* 1983; **2**: 1068–1069.