

First-trimester determination of fetal gender by ultrasound

Z. Efrat, O. O. Akinfenwa and K. H. Nicolaidis

The Harris Birthright Research Centre for Fetal Medicine, King's College Hospital Medical School, London, UK

Key words: ULTRASONOGRAPHY, FIRST TRIMESTER, FETAL GENDER, FETAL SEX, NUCHAL TRANSLUCENCY

ABSTRACT

Objective To assess the accuracy of fetal sex determination at 11–14 weeks of gestation.

Methods Fetal gender assessment by ultrasound was prospectively carried out in 172 singleton pregnancies at 11–14 weeks of gestation immediately before chorionic villus sampling for karyotyping. The genital region was examined in a midsagittal plane and the fetal gender was assigned as male if the angle of the genital tubercle to a horizontal line through the lumbosacral skin surface was greater than 30° and female when the genital tubercle was parallel or convergent (less than 30°) to the horizontal line.

Results The accuracy of sex determination increased with gestation from 70.3% at 11 weeks, to 98.7% at 12 weeks and 100% at 13 weeks. In the male fetuses, there was a significant increase in the angle of the genital tubercle from the horizontal with crown–rump length. Male fetuses were wrongly assigned as female in 56% of cases at 11 weeks, 3% at 12 weeks and 0% at 13 weeks. In contrast, only 5% of the female fetuses at 11 weeks were incorrectly assigned as male and this false-positive rate was 0% at 12 and 13 weeks.

Conclusion The clinical value of determination of fetal sex by ultrasound is in deciding whether to carry out prenatal invasive testing in pregnancies at risk of sex-linked genetic abnormalities, because invasive testing would be necessary only in pregnancies with male fetuses. Our results suggest that a final decision on invasive testing for sex-linked conditions should be undertaken only after 12 weeks of gestation.

INTRODUCTION

Prenatal determination of fetal gender by ultrasound during the second and third trimesters of pregnancy is based on the demonstration of and the size of the penis in the

male, or labial folds in the female. However, there is no appreciable difference in the size of the penis and the clitoris until after 14 weeks of gestation¹. There is some evidence that, in the early second trimester, fetal gender can be accurately predicted by assessment of the direction in which the genital tubercle points (cranial for males and caudal for females²) and also by the sagittal sign, whereby examination of the genital region in the midline sagittal plane demonstrates a caudal notch in females and a cranial notch in males^{3,4}.

The aim of this study was to determine the accuracy of sex determination by ultrasound at 10–14 weeks, which is likely to be the gestation of the first routine anomaly scan in pregnancy^{5,6}.

MATERIALS AND METHODS

Fetal gender assessment by ultrasound was prospectively carried out in 172 singleton pregnancies at 11–14 weeks of gestation immediately before chorionic villus sampling for karyotyping. The patients were attending our unit for assessment of risk for trisomy 21 because of a combination of maternal age and increased fetal nuchal translucency thickness. The ultrasound examinations, which were carried out transabdominally using a curvilinear probe, took 10–15 min to complete. The genital region was examined in a midsagittal plane with the fetus horizontal (parallel) to the probe in a supine position with no extension of the limbs or spine. A photograph was taken and the angle of the genital tubercle to a horizontal line through the lumbosacral skin surface was measured (Figure 1). The fetal gender was assigned as male if the angle was greater than 30° and female if the phallus was parallel or convergent (less than 30°) to the horizontal line. The fetal sex was subsequently ascertained by the karyotype obtained from the chorionic villus sample.

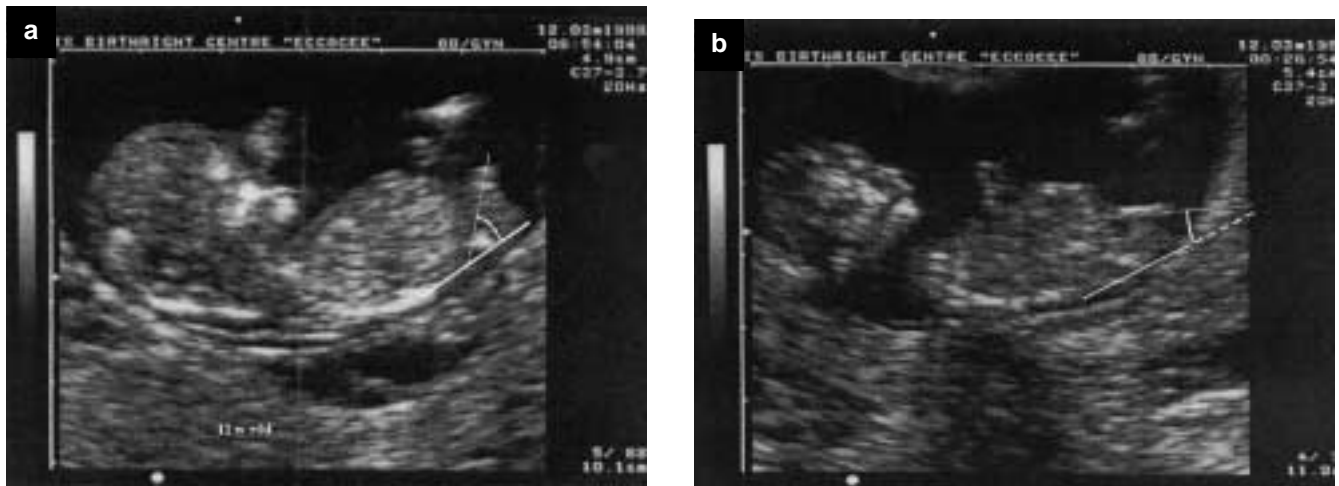


Figure 1 (a) Male fetus with acute angle of the penis shown. (b) Female fetus with converging angle of the clitoris shown

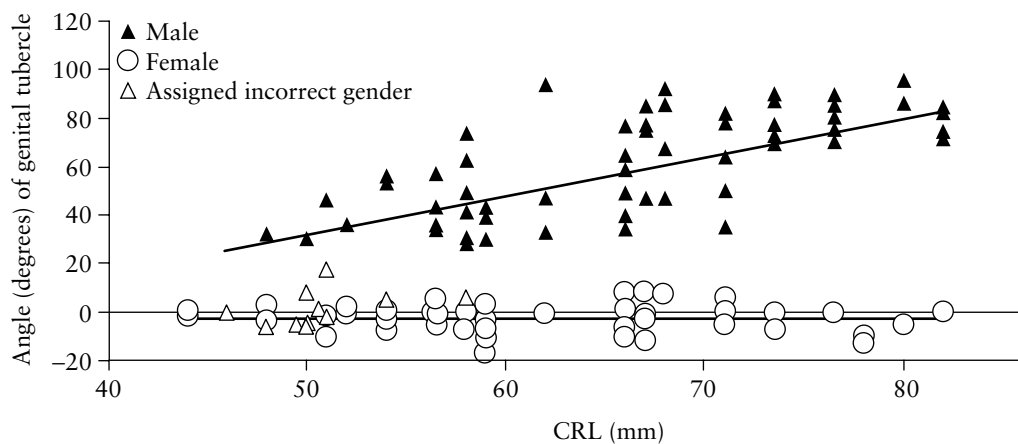


Figure 2 Difference in angle of genitalia with gestational age, assessed by crown-rump length (CRL)

RESULTS

The median gestation at the time of assessment was 12 weeks (range 11 weeks–13 weeks + 6 days) and the median crown-rump length was 62 mm (range 44–83 mm). Successful examination of the genital region was achieved in 157 (91.3%) of the 172 fetuses; in the other 15 cases, examination was not possible, owing to the fetal lie or maternal obesity (Table 1). Cytogenetic analysis demonstrated a male karyotype in 83 cases and female karyotype in 74 cases; there were four cases of trisomy 21, and one case each of trisomy 18 and Klinefelter syndrome. The fetal sex was correctly determined by ultrasound in 145 (92.3%) of the 157 cases. The accuracy of sex determination increased with gestation from 70.3% at 11 weeks, to 98.7% at 12 weeks and 100% at 13 weeks (Table 2). In the male fetuses, there was a significant increase in the angle of the genital tubercle from the horizontal with crown-rump length ($r = 0.797$; $p < 0.001$) (Figure 2).

DISCUSSION

The findings of this study demonstrate that determination of fetal sex by examination of the angle of the genital tubercle provided accurate prediction of the fetal sex from

Table 1 Gestational age distribution of the singleton pregnancies that were examined by ultrasound for the determination of fetal gender

Gestational age (weeks)	CRL (mm)	n	Gender identified	
			n	%
11–11 + 6	43.4–55.3	40	37	92.5
12–12 + 6	55.4–67.9	83	77	92.8
13–13 + 6	68.0–83.9	49	43	87.8
Total		172	157	91.3

CRL, crown-rump length

12 weeks of gestation. In females, the angle of the clitoris ranged from -20 to $+20^\circ$ from the horizontal. In male fetuses from 12 weeks, the angle was more than 30° and increased with advancing gestation. These findings are compatible with the embryological development of the external genitalia.

The structural precursors of the external genitalia are present but are not sufficiently differentiated to make a clear distinction on examination of the genitalia until after 10 weeks of gestation. However, from 12 weeks, there are distinct changes in the structure of the urogenital sinus. A process of gender-specific changes takes place. In males, the urogenital sinus is replaced by the scrotal and urethral

Table 2 Accuracy of sonographic determination of fetal gender in cytogenetic male and female fetuses between 11 and 14 weeks of gestation

Gestational age (weeks)	Crown-rump length (mm)	Cytogenetic male	Cytogenetic female	Sonographically assigned as male	Sonographically assigned as female
11-11 + 6	43.4-55.3	18	19	8/18 (44.4%)	18/19 (94.7%)
12-12 + 6	55.4-67.9	35	42	34/35 (97.1%)	42/42 (100%)
13-13 + 6	68.0-83.9	30	13	30/30 (100%)	13/13 (100%)
Total		83	74		

CRL, crown-rump length

raphe; closure of the urogenital sinus takes place in a zip-like fashion starting from the caudal end of the embryo. This process, combined with elongation of the genital tubercle, gradually displaces the phallus in a rostral direction. In the female the urogenital sinus remains open and ultimately becomes the vestibule of the vagina⁷. Significant differences in the rate of penile and clitoral growth become evident in the second trimester; the majority of prenatal growth of the penis occurs after 14 weeks' gestation at an almost linear rate¹.

The clinical value of determination of fetal sex by ultrasound is in deciding whether to carry out prenatal invasive testing in pregnancies at risk of sex-linked genetic abnormalities, because invasive testing would be necessary only in pregnancies with male fetuses. In our study, 56% of male fetuses were wrongly assigned as female at 11 weeks; this false-negative rate decreased to 3% at 12 weeks and 0% at 13 weeks. In contrast, only 5% of the female fetuses at 11 weeks were incorrectly assigned as male and this false-positive rate was 0% at 12 and 13 weeks. Consequently, our results suggest that a final decision on invasive testing for sex-linked conditions should be undertaken only after 12 weeks of gestation. A larger study would be required to confirm the accuracy rates of this study, prior to introduction of this technique into routine practice.

ACKNOWLEDGEMENT

This study was supported by the Fetal Medicine Foundation (charity no. 1037166).

REFERENCES

1. Feldman KW, Smith DW. Fetal phallic growth and penile standards for newborn male infants. *J Pediatr* 1975;86:395-8
2. Bronshtein M, Rottem S, Yoffe N, Blumenfeld Z, Brandes JM. Early determination of fetal sex using transvaginal sonography: technique and pitfalls. *J Clin Ultrasound* 1990;18:302-6
3. Emerson DS, Felker RE, Brown DL. The sagittal sign. An early second trimester sonographic indicator of fetal gender. *J Ultrasound Med* 1989;8:293-7
4. Natsuyama E. Sonographic determination of fetal sex from twelve weeks of gestation. *Am J Obstet Gynecol* 1984;149:748-57
5. Souka AP, Nicolaides KH. Diagnosis of fetal abnormalities at the 10-14-week scan. *Ultrasound Obstet Gynecol* 1997;10:429-42
6. Souka AP, Snijders RJ, Novakov A, Soares W, Nicolaides KH. Defects and syndromes in chromosomally normal fetuses with increased nuchal translucency thickness at 10-14 weeks of gestation. *Ultrasound Obstet Gynecol* 1998;11:391-400
7. Marshall FF. Embryology of the lower genitourinary tract. *Urol Clin North Am* 1978;5:3-15