

# Megacystis at 10–14 weeks of gestation: chromosomal defects and outcome according to bladder length

A. W. LIAO, N. J. SEBIRE, L. GEERTS, S. CICERO and K. H. NICOLAIDES

Harris Birthright Research Centre for Fetal Medicine, King's College Hospital Medical School, London, UK

**KEYWORDS:** chromosomal defects; fetal bladder; megacystis; ultrasound diagnosis

## ABSTRACT

**Aims** To examine the prevalence of chromosomal defects and outcome of fetuses with megacystis at 10–14 weeks of gestation.

**Methods** At the 10–14-week scan fetal megacystis was defined by a longitudinal bladder diameter of 7 mm or more. In 145 such fetuses the fetal karyotype and pregnancy outcome were examined in relation to the longitudinal diameter of the fetal bladder.

**Results** Chromosomal defects, mainly trisomies 13 and 18, were present in 30 cases. In the group with longitudinal bladder diameter of 7–15 mm the incidence of chromosomal defects was 23.6% (26/110), whereas in those with bladder diameter >15 mm the incidence was 11.4% (4/35). The fetal nuchal translucency (NT) was above the 95th centile of the normal range for crown–rump length in a higher proportion of cases with abnormal rather than normal karyotype (76.7% compared to 31.3%; Chi-square  $P < 0.0001$ ). The expected number of cases of trisomy 21, estimated on the basis of maternal age, gestational age and fetal NT, was 6.2 rather than the observed 2 and the corresponding numbers for trisomies 13 or 18 were 4.2 for expected and 24 for observed. In the chromosomally normal group with longitudinal bladder diameter of 7–15 mm follow-up scans demonstrated spontaneous resolution of the megacystis in 90% of the cases and enlargement of the megacystis and/or the development of echogenic kidneys in 10%. In contrast, none of the cases with bladder diameter >15 mm demonstrated spontaneous resolution of the megacystis.

**Conclusions** In fetal megacystis with longitudinal bladder diameter of 7–15 mm there is a risk of about 25% that the fetus will have a chromosomal defect but in the chromosomally normal group there is spontaneous resolution of the megacystis in about 90% of cases. If the

bladder diameter is >15 mm the risk of chromosomal defects is about 10% and in the chromosomally normal group the condition is invariably associated with progressive obstructive uropathy. Copyright © 2003 ISUOG. Published by John Wiley & Sons, Ltd.

## INTRODUCTION

Fetal megacystis at 10–14 weeks of gestation, defined by a longitudinal bladder diameter of 7 mm or more, is found in about 1 in 1500 pregnancies (Figure 1)<sup>1</sup>. In a screening study involving 24 492 singleton pregnancies there were 15 cases of megacystis and three had chromosomal defects; in the chromosomally normal group there were seven cases with spontaneous resolution and four with progression to severe obstructive uropathy<sup>1</sup>. This study examines the findings in an expanded series of 145 cases of megacystis.

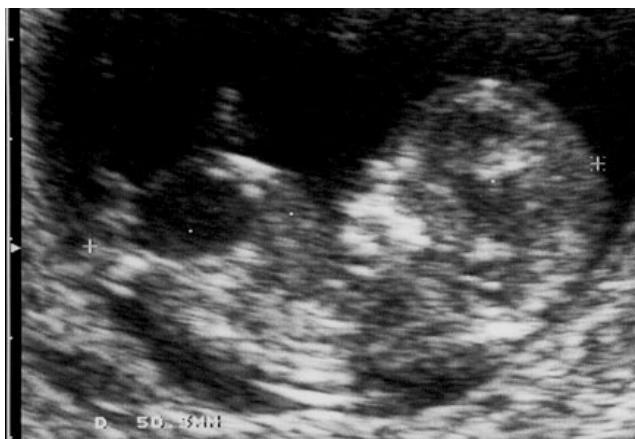## METHODS

Since September 1992 an ultrasound screening study has been implemented at the Harris Birthright Research Centre for Fetal Medicine involving measurement of fetal nuchal translucency (NT) at 10–14 weeks of gestation<sup>2</sup>. We also examine patients referred from other hospitals because of suspected fetal defects at their routine first-trimester scan.

In our center the fetal crown–rump length (CRL) and NT are measured and the fetus is examined for any obvious defects. All ultrasound findings are recorded onto a computer database at the time of the ultrasound examination. One of the abnormalities searched for is megacystis and in such cases the longitudinal diameter of the bladder is recorded and follow-up scans are undertaken<sup>1</sup>. Details on pregnancy outcome were obtained from the patients themselves or their hospitals.

Correspondence to: Prof. K. H. Nicolaides, Harris Birthright Research Centre for Fetal Medicine, King's College Hospital Medical School, Denmark Hill, London SE5 9RS, UK (e-mail: kypros@fetalmedicine.com)

Accepted: 20 January 2003



**Figure 1** A 12-week fetus with megacystis.

A computer search of the database was made to identify all singleton pregnancies with fetal megacystis at the 10–14-week scan. The prevalence of chromosomal abnormalities and pregnancy outcome were examined in relation to the longitudinal diameter of the fetal bladder.

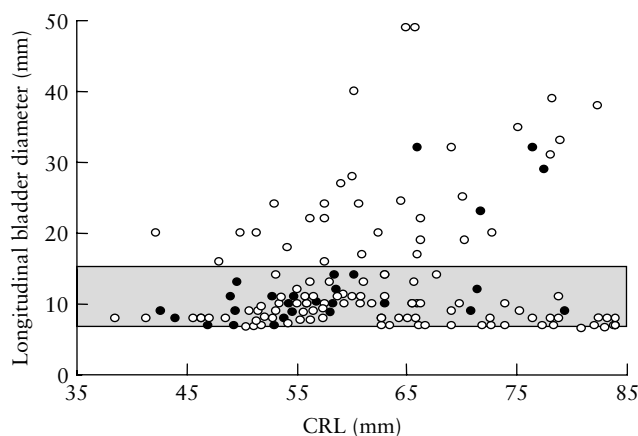
**RESULTS**

During the study period (1992–2002) we examined 166 cases of megacystis. Twenty-one cases were excluded from further analysis because in 15 cases the pregnancies were terminated and the parents refused fetal karyotyping and in six cases the patients were lost to follow-up. In the remaining 145 cases the median maternal age was 33 (range, 19–46) years, the median gestation was 12 (range, 10–14) weeks, the median CRL was 60 (range, 38–84) mm and the median longitudinal diameter of the fetal bladder was 10 (range, 7–49) mm. In 135 cases the fetus was male and in ten it was female.

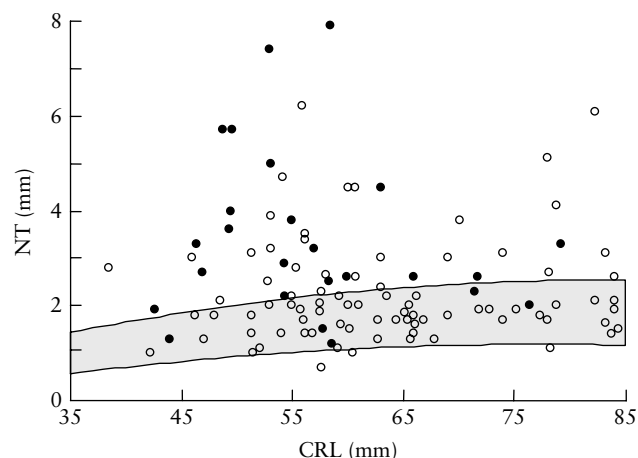
In 30 cases the fetal karyotype, determined following chorionic villus sampling, was abnormal (29 male and one female); in 115 cases the fetal karyotype was normal or phenotypically normal babies were born (106 male and nine female). The chromosomal defects included 17 cases of trisomy 13, seven cases of trisomy 18, two cases of trisomy 21 and one case each of triploidy, trisomy 4, mosaic trisomy 15, and unbalanced translocation involving chromosomes 14 and 20.

**Table 1** Prevalence of chromosomal defects and outcome of fetuses with megacystis according to longitudinal bladder diameter

	Longitudinal bladder diameter (mm)	
	7–15	> 15
Total	110	35
Abnormal karyotype	26 (23.6%)	4 (11.4%)
Normal karyotype with follow up	79	30
Spontaneous resolution	71 (89.9%)	0
Obstructive uropathy	8 (10.1%)	30 (100%)



**Figure 2** Longitudinal bladder diameter for crown–rump length (CRL) in chromosomally normal (○) and abnormal (●) fetuses with megacystis. In the group with bladder diameter of 7–15 mm (gray zone) the incidence of chromosomal defects was 23.6% whereas in those with bladder diameter > 15 mm the incidence was 11.4%.



**Figure 3** Fetal nuchal translucency (NT) in chromosomally normal (○) and abnormal (●) fetuses with megacystis plotted on the normal range for gestation (5th and 95th centiles). CRL, crown–rump length.

In the group with longitudinal bladder diameter of 7–15 mm the incidence of chromosomal defects was 23.6% (26/110), whereas in those with bladder diameter > 15 mm the incidence was 11.4% (4/35; Chi-square  $P = 0.19$ ) (Table 1, Figure 2). In the chromosomally abnormal compared to the normal group the median maternal age was similar (35 vs. 33 years; Mann–Whitney  $P = 0.4$ ), the median CRL was shorter (57 vs. 62 mm; Mann–Whitney  $P = 0.03$ ), the median fetal NT was higher (3.1 vs. 1.9 mm; Mann–Whitney  $P < 0.0001$ ) and the NT was above the 95th centile of the normal range for CRL in a higher proportion of cases (76.7% or 23/30 vs. 31.3% or 36/115; Chi-square  $P < 0.0001$ ) (Figure 3). In the chromosomally normal group there was a significant association between fetal NT and longitudinal bladder diameter ( $r = 0.22$ ,  $P = 0.02$ ); this association was not significant in the chromosomally abnormal group ( $r = -0.19$ ,  $P = 0.29$ ).

In the 145 fetuses with megacystis the expected number of cases of trisomy 21, estimated on the basis of maternal age, gestational age and fetal NT, was 6.2 rather than the observed 2 (Fisher's exact test  $P = 0.28$ )<sup>2,3</sup>. The corresponding numbers for trisomies 13 or 18 were 4.2 for expected and 24 for observed (Fisher's exact test  $P < 0.0001$ )<sup>2,4</sup>. In 26/30 chromosomally abnormal cases the pregnancies were terminated at the request of the parents and the other four cases resulted in spontaneous fetal death.

In the chromosomally normal group with bladder length 7–15 mm ( $n = 84$ ), there was one miscarriage at 16 weeks and four terminations of pregnancy (TOPs) for major fetal defects. In the remaining 79 cases, there were eight TOPs because of enlargement of the megacystis and/or the development of echogenic kidneys and 71 with spontaneous resolution of the megacystis by 20 weeks of gestation and they all resulted in healthy live births. Therefore, after exclusion of the miscarriage and the TOPs for other defects, the incidence of obstructive uropathy in the group with bladder length 7–15 mm was 10.1% (8/79) (Table 1).

In the chromosomally normal group with bladder length > 15 mm ( $n = 31$ ), there was one TOP for a major fetal defect. In the remaining 30 cases the fetal kidneys were echogenic at the 10–14-week scan or follow-up scans demonstrated enlargement of the megacystis and/or the development of echogenic kidneys (Table 1). In these 30 pregnancies there were eight miscarriages or fetal deaths at 13–20 weeks and 22 TOPs for obstructive uropathy. In two cases vesico-amniotic shunting was carried out at 14 weeks of gestation but in both cases there was miscarriage within 1 week of the procedure.

## DISCUSSION

This study has demonstrated that in fetal megacystis at 10–14 weeks of gestation if the longitudinal diameter of the fetal bladder is 7–15 mm there is a risk of about 25% that the fetus will have a chromosomal defect, mainly trisomy 13 or 18. In the chromosomally normal group there is spontaneous resolution of the megacystis without any obvious adverse consequence on the development of the urinary system in about 90% of cases. In contrast, in megacystis with bladder diameter > 15 mm the risk of chromosomal defects is about 10% but in the chromosomally normal group the condition is invariably associated with progressive obstructive uropathy. The relation between bladder length and the incidence of chromosomal defects in fetuses with megacystis was also highlighted in the study of Favre *et al.*, who reported trisomies 13, 18 or 21 in 4/5 fetuses with bladder length of 9–15 mm but in none of the ten cases with measurements > 15 mm<sup>5</sup>.

Megacystis is associated with increased NT, which was observed in about 75% of those with chromosomal abnormalities and in about 30% of those with normal karyotype. The underlying mechanism for the increased NT in fetal megacystis may be thoracic compression,

in a similar way to that observed in diaphragmatic hernia and a wide range of skeletal dysplasias that are associated with a narrow thoracic cage<sup>6</sup>. The most commonly associated chromosomal defects are trisomies 13 and 18 and although in the majority of affected fetuses the NT was increased, the presence of megacystis increases the likelihood for these chromosomal defects by a factor of six. Furthermore, the data demonstrate that, as with other fetal abnormalities such as exomphalos and ventriculomegaly, chromosomal defects are more commonly associated with the milder, rather than the more severe, degrees of the given abnormality<sup>7</sup>.

In pregnancies with megacystis of 7–15 mm the parents can be reassured that once the fetal karyotype is found to be normal in about 90% of cases the megacystis will resolve without any obvious adverse effects on renal development and function. The presence of smooth muscle in the bladder and autonomic innervation occur only after 13 weeks; before this gestation the bladder wall consists of epithelium and connective tissue with no contractile elements<sup>8,9</sup>. It could therefore be postulated that the majority of cases of fetal megacystis of 7–15 mm may be a consequence of temporary malfunction during a critical stage in the development of bladder function. Nevertheless, in about 10% of cases there may be progression to severe obstructive uropathy. Two previous case reports also highlighted the possibility of progression to severe disease. Stiller reported an 11-week fetus with megacystis (10 mm) and normal kidneys but at 13 weeks there was enlargement of the bladder (30 mm) and bilateral hydronephrosis with reduced amniotic fluid<sup>10</sup>. Zimmer and Bronshtein reported an 11-week fetus with bladder diameter of 13 mm and 1 week later the bladder increased to 30 mm with evidence of hydronephrosis<sup>11</sup>.

Megacystis > 15 mm is associated with severe obstructive uropathy and renal dysplasia. These findings are compatible with those of several case reports in which pathological examination after TOP for progressive megacystis showed urethral atresia, hypertrophic bladder, dysplastic kidneys and atrophied abdominal muscles<sup>5,12–14</sup>. Although animal studies have demonstrated that the renal damage in obstructive uropathy can be reduced by intrauterine surgery, the data from vesico-amniotic shunting in human fetuses have not provided conclusive evidence that such interventions are beneficial<sup>15–18</sup>. It is possible that by mid-gestation, when surgery is usually undertaken, irreversible renal damage may have already occurred. The extent to which first-trimester decompression would be beneficial remains uncertain<sup>19</sup>.

## ACKNOWLEDGMENT

The study was supported by a grant from The Fetal Medicine Foundation (Registered Charity No. 1037116).

## REFERENCES

1. Sebire NJ, Von Kaisenberg C, Rubio C, Nicolaides KH. Fetal megacystis at 10–14 weeks of gestation. *Ultrasound Obstet Gynecol* 1996; 8: 387–390.

2. Snijders RJ, Noble P, Sebire N, Souka A, Nicolaides KH. UK multicentre project on assessment of risk of trisomy 21 by maternal age and fetal nuchal-translucency thickness at 10–14 weeks of gestation. Fetal Medicine Foundation First Trimester Screening Group. *Lancet* 1998; **352**: 343–346.
3. Snijders RJ, Sundberg K, Holzgreve W, Henry G, Nicolaides KH. Maternal age- and gestation-specific risk for trisomy 21. *Ultrasound Obstet Gynecol* 1999; **13**: 167–170.
4. Snijders RJ, Sebire NJ, Nicolaides KH. Maternal age and gestational age-specific risk for chromosomal defects. *Fetal Diagn Ther* 1995; **10**: 356–367.
5. Favre R, Kohler M, Gasser B, Muller F, Nisand I. Early fetal megacystis between 11 and 15 weeks of gestation. *Ultrasound Obstet Gynecol* 1999; **14**: 402–406.
6. Souka AP, Snijders RJ, Novakov A, Soares W, Nicolaides KH. Defects and syndromes in chromosomally normal fetuses with increased nuchal translucency thickness at 10–14 weeks of gestation. *Ultrasound Obstet Gynecol* 1998; **11**: 391–400.
7. Nicolaides KH, Snijders RJM, Gosden CM, Berry C, Campbell S. Ultrasonographically detectable markers of fetal chromosomal abnormalities. *Lancet* 1992; **340**: 704–707.
8. Gilpin SA, Gosling JA. Smooth muscle in the wall of the developing human urinary bladder and urethra. *J Anat* 1983; **137**: 503–512.
9. Newman J, Antonakopoulos GN. The fine structure of the human fetal urinary bladder: development and maturation. *J Anat* 1989; **166**: 135–150.
10. Stiller R. Early ultrasonic appearance of fetal bladder outlet obstruction. *Am J Obstet Gynecol* 1989; **160**: 584–585.
11. Zimmer EZ, Bronshtein M. Fetal intra-abdominal cysts detected in the first and early second trimester by transvaginal sonography. *J Clin Ultrasound* 1991; **19**: 564–567.
12. Bulic M, Podobnik M, Korenic B, Bistricki J. First-trimester diagnosis of low obstructive uropathy: an indicator of initial renal function in the fetus. *J Clin Ultrasound* 1987; **15**: 537–541.
13. Fried S, Appelman Z, Caspi B. The origin of ascites in prune belly syndrome – early sonographic evidence. *Prenat Diagn* 1995; **15**: 876–877.
14. Cazorla E, Ruiz F, Abad A, Monleon J. Prune belly syndrome: early antenatal diagnosis. *Eur J Obstet Gynecol* 1997; **72**: 31–33.
15. Glick PL, Harrison MR, Noall RA, Villa RL. Correction of congenital hydronephrosis *in utero*. III. Early mid-trimester ureteral obstruction produces renal dysplasia. *J Pediatr Surg* 1983; **18**: 681–687.
16. Harrison MR, Nakayama DK, Noall R, De Lorimer AA. Correction of congenital hydronephrosis *in utero*. II. Decompression reverses the effect of obstruction on the fetal lung and urinary tract. *J Pediatr Surg* 1982; **17**: 965–974.
17. Glick PL, Harrison MR, Adzick NS, Noall RA, Villa RL. Correction of congenital hydronephrosis *in utero*. IV. *In utero* decompression prevents renal dysplasia. *J Pediatr Surg* 1984; **19**: 649–657.
18. Elder JS, Duckett JW, Snyder HM. Intervention for foetal obstructive uropathy: has it been effective? *Lancet* 1987; **2**: 1007–1010.
19. Carroll SGM, Soothill PW, Tizard J, Kyle PM. Vesicocentesis at 10–14 weeks of gestation for treatment of fetal megacystis. *Ultrasound Obstet Gynecol* 2001; **18**: 366–370.